

Clinical and radiographic data for the application of hyaDENT BG[®] gel and Bio-Oss Collagen[®] in periodontitis

Velitchka Dosseva-Panova¹, Antoaneta Mlachkova¹, Zdravka Pashova-Tasseva¹, Ivan Ivanov¹, Hristina Maynalovska¹, Ekaterina Tosheva², Kamen Kotsilkov¹

1. Medical University of Sofia, Bulgaria, Faculty of Dental Medicine, Department of Periodontology,
2. Department of Statistics and Econometrics, Faculty of Applied Informatics and Statistics, University of National and World Economy, Sofia, Bulgaria

Abstract

This study aimed to evaluate the use of hyaluronic acid in periodontal regenerative procedures for the treatment of angular defects. Data demonstrated it plays a significant role in tissue healing, hydration, and modulation of inflammation. Its ability to inhibit pro-inflammatory cytokines and to support collagen formation makes it a valuable adjunct in periodontal therapy. The research employed a cross-linked hyaluronic gel (hyaDENT BG[®]) combined with a bovine bone substitute (Bio-Oss[®] Collagen) to assess clinical and radiographic outcomes. Eight patients with Stage III periodontitis and overall 14 intrabony defects underwent surgical treatment involving flap elevation, root surface decontamination, application of hyaluronic gel, and graft placement. Clinical parameters such as probing pocket depth, clinical attachment loss, and gingival recession were measured before and after treatment. The results demonstrated significant improvements, with pocket depth decreasing from an average of 7.29 mm to 3.07 mm, and attachment gain of 4.36 mm, indicating enhanced periodontal stability. Radiographic assessments revealed a bone fill of 4.43 mm/mean, representing 88.6% defect fill, thereby confirming the regenerative potential of the hyaluronic acid when combined with graft materials. While these findings are promising, the authors emphasize the need for further research to validate these results across diverse clinical conditions and to establish standardized treatment protocols. In conclusion, hyaluronic acid appears to be a promising adjunct in periodontal regeneration due to its biological properties, easy manipulation, safety, and cost-effectiveness.

Keywords: angular defects, bone graft, hyaluronic acid, periodontitis

Introduction

Hyaluronic acid (HA) is a glycosaminoglycan with a molecular weight of 4 000 to 20 000 000 Da that is a key constituent of the extracellular matrix, where it plays a crucial role in tissue morphogenesis, cell migration, differentiation, and adhesion processes. (1) It is synthesized by HA synthase enzymes presented in fibroblasts, keratinocytes, periodontal ligament cells,

cementoblasts, osteoblasts. (2) HA is found abundant in gingival connective tissue and periodontal ligament, but less quantity in alveolar bone and cementum. (2)

There are some positive biologic characteristics as its ability to help tissue healing and to maintain tissue hydration. Moreover it may modulate inflammatory responses by inhibiting pro-inflammatory cytokines such as IL-1 β , TNF- α , and prostaglandins, and in this way reduces the inflammation. (1,3)

In periodontology, topical application of HA gel has been used adjunctively with scaling and root planing (SRP) to enhance clinical outcomes. Furthermore, hyaluronic acid serves as a valuable adjunct in periodontal surgery and it has been shown to be integrated into surgical protocols together with bone grafting biomaterials. (1,3-7) Probably, HA's viscoelastic properties help in maintaining graft stability at the defect site and may facilitate better integration of the graft material with host bone in the recipient surgical area. (2)

Data suggested that HA supports collagen matrix formation and enhances vascularization. (8,9)

Various types of grafts, including autografts, allografts, xenografts, and alloplastic materials, are commonly used for the repair and reconstruction of bone defects and may be combined with hyaluronic acid to enhance regenerative outcomes. (3,8,9)

hyaDENT BG (hyaDENT BG® gel, BioScience GmbH, Germany) is a sterile gel composed of cross-linked hyaluronic acid (xHyA). Cross-linked hyaluronic acid (xHyA) is produced by forming new bonds between linear or native HA molecules that join together. Native HA degrades for a few hours to a few days. In contrast, xHyA possess extended degradation until several weeks or months. Due to this property, HA can be also useful in graft stabilization. According to the manufacturer, the composition includes 1.6% cross-linked hyaluronic acid (xHyA) as well as 0.2% natural hyaluronic acid. It is designed for use in procedures such as soft tissue recession surgery, guided tissue regeneration (GTR), and guided bone regeneration (GBR). The gel contains surgical-grade, highly purified cross-linked hyaluronic acid with a specifically tailored molecular weight, and derived from non-animal sources, making it suitable for dental applications. It can be applied directly to the surgical site, even in the presence of blood, and can also be combined with other biomaterials such as bone grafts or collagen membranes.

The authors suggested that the bacteriostatic properties of hyaluronic acid may reduce microbial load in treated sites in patients with periodontitis and benefit periodontal surgery. (10) High concentrations of HA showed the greatest bacteriostatic effect on the tested bacterial strains, especially on *Aggregatibacter actinomycetemcomitans*, *Prevotella oris*, *Staphylococcus aureus*, and *Propionibacterium acnes*. Based on their results, Pirnazar et al. concluded that HA is therapeutically effective in tissue regeneration procedures because of its ability to minimize the microbial contamination of surgical wounds. (10)

Moreover, Asparuhova et al. showed HA stimulates the growth of osteoprogenitor cells and may enhance the expression of genes encoding bone matrix proteins like transforming growth factor- β 1 (TGF- β 1) and fibroblast growth factor-1 (FGF-1). Thus, the HA addition during periodontal surgery procedures may maintain the self-renewal and the differentiation processes. (11)

Similar outcomes have been reported, showing that cross-linked HA is associated with high PDL cell viability, increased proliferation, and early—but not late—osteogenic differentiation in culture media. (12)

Aim

The aim of the current study was to evaluate the efficacy of hyaluronic acid in the treatment of infraosseous periodontal defects using bovine bone substitute ((Bio-Oss® Collagen, Geistlich Pharma, Wolhusen, Switzerland).

Material and Methods

This research complied with the procedural guidelines of the Research Ethics Committee at the Medical University of Sofia (KENIMUS).

Ethics statement: All participants signed informed consent forms. This research complied with the Rules of Procedure of the Research Ethics Committee at Medical University of Sofia (KENIMUS).

Inclusion criteria: patients in good general health, diagnosed with Stage III periodontitis, with a deep periodontal pocket and an angular defect showing an intra-osseous component of ≥ 3 mm on radiographic examination; teeth must be vital or with good endodontic status.

Exclusion criteria: heavy smokers, individuals with systemic conditions and diseases, pregnancy or lactation, Class III furcation involvement, tooth mobility.

Patients were screened and enrolled based on the specified inclusion and exclusion criteria. The diagnosis was established after clinical examination and confirmed radiographically. Clinical examinations were performed with a calibrated UNC 15 periodontal probe (Hu Friedy, USA).

Patients received detailed information regarding the surgical procedure and signed informed consent. The study protocol received approval from the Institutional Ethical Committee. Patients underwent initial therapy consisting of scaling, polishing, and root planing. A schedule of activities was prepared for the period from the initial visits to the completion of the study period of up to 1 year. A surgical protocol was followed and postoperative care was ensured.

Table 1 presents the planned measurement schedule.

Table 1. Outline of intended clinical and radiographic evaluations.

| Parameter | Assessment | Evaluation Timeline |
|--|--|-------------------------------|
| Clinical Attachment Level (CAL) | Change in CAL between baseline and post-surgical data, in mm | Baseline and 6 months post-op |
| Periodontal Pocket Depth (PPD) | Change in PPD between baseline and post-surgical data, in mm | Baseline and 6 months post-op |
| Gingival Recession (GR) | Change in GR between baseline and post-surgical data, in mm | Baseline and 6 months post-op |
| Bone Fill (BF) | Change in BF between baseline and post-surgical data, in mm | Baseline and 9 months post-op |

Pre-surgical period: Patients received instructions on proper personal oral hygiene practices. Scaling was performed using both ultrasonic and hand instruments. A reassessment was conducted at six weeks to evaluate the patient's response to non-surgical therapy and to confirm the need for periodontal surgery.

All clinical measurements during periodontal treatment were performed by calibrated periodontists. An intra-class correlation coefficient (ICC) of ≥ 0.9 was established to ensure examiner reliability.

Description of the surgical procedure - following steps were scheduled:

- Terminal anesthesia was administered to anesthetize the area of the surgical procedure.
- A flap was designed using a blade, employing a conservative, minimally invasive surgical technique.
- Scaling and root planing were performed using ultrasonic devices and hand instruments.
- The bone defect was evaluated for anatomical features, including depth, width, and the condition of the surrounding bone walls. Granulation tissue was removed.
- The root surface was conditioned with EDTA gel for two minutes (24% EDTA gel, pH 6.7; PrefGel, Straumann, Basel, Switzerland) and then thoroughly rinsed with saline.
- Hyadent BG (hyaluronic acid, hyaDENT BG, Bioscience, Germany) was applied to the root surface.
- The bone substitute material was mixed with Hyadent BG and applied to the bone defect.
- The flap was repositioned and sutured.
- Postoperative care instructions were provided.

Statistical analysis:

Data were analyzed using IBM SPSS Statistics (Version 22). The significance level was set at $p < 0.05$ for hypothesis testing, indicating that null hypotheses would be rejected at this threshold. The following statistical methods were employed: descriptive analysis for estimation of central tendency (such as mean, median) and dispersion (including standard deviation, range); the Mann-Whitney non-parametric test for comparison of clinical parameters between independent samples (two groups formed according to the values of different variables); the Wilcoxon signed-rank test for detection of statistically significant differences within related samples (before and after received surgical therapy).

Results

Eight patients aged between 32 and 61 years (48.38 ± 10) with a total of 14 teeth with doubtful prognosis, were included in this study. Each patient received periodontal surgery involving a bone graft procedure using a xenograft (Bio-Oss® Collagen) mixed with a hyaluronic acid gel (hyaDENT BG).

All patients were diagnosed with Stage III periodontitis, evenly distributed between Grade B and Grade C. A total of 14 intrabony defects were treated: 8 located in the maxilla and 6 in the mandible. The mean distance from the alveolar bone crest to the bottom of the defect on baseline radiographs was 5 ± 0.877 mm, while the mean intrabony depth measured intra-operatively was 4.43 ± 0.938 mm. The average radiographic defect angle was $36.64^\circ \pm 6.021^\circ$.

Of the 14 defects, 6 were classified as 2-wall defects and 8 as 3-wall defects.

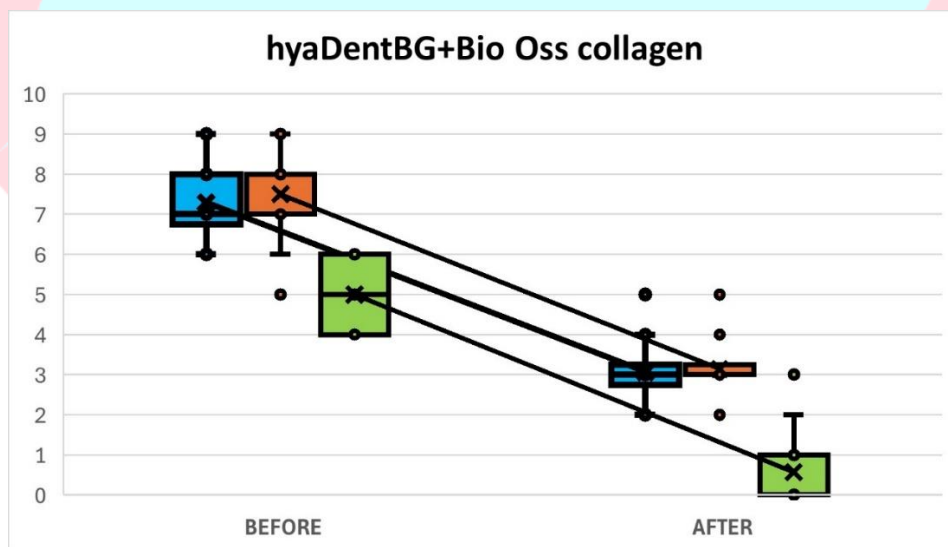
Clinical and radiographic characteristics of the studied cases are recorded and briefly presented in Table 2.

Table 2. General recorded information of the studied group of defects.

| | PPD1 | CAL1 | GR1 | Intra-operative depth | Defect angle | R1 | PPD2 | CAL2 | GR2 | R2 | BF |
|--------------------|------|------|------|-----------------------|--------------|------|------|------|------|------|------|
| N | 14 | 14 | 14 | 14 | 14 | 14 | 14 | 14 | 14 | 14 | 14 |
| Mean | 7.29 | 7.50 | 0.43 | 4.43 | 36.64 | 5.00 | 3.07 | 3.14 | 0.29 | 0.57 | 4.43 |
| Median | 7.00 | 8.00 | 0.00 | 4.00 | 35.00 | 5.00 | 3.00 | 3.00 | 0.00 | 0.00 | 4.50 |
| Standard Deviation | 0.99 | 1.09 | 0.51 | 0.94 | 6.02 | 0.88 | 0.83 | 0.77 | 0.47 | 0.94 | 1.22 |
| Range | 3 | 4 | 1 | 3 | 20 | 2 | 3 | 3 | 1 | 3 | 5 |
| Minimum | 6 | 5 | 0 | 3 | 25 | 4 | 2 | 2 | 0 | 0 | 1 |
| Maximum | 9 | 9 | 1 | 6 | 45 | 6 | 5 | 5 | 1 | 3 | 6 |

Legend of Table 2: PPD1 - periodontal pocket depth before surgery, CAL1 - clinical attachment loss before surgery, GR1 - gingival recession before surgery, R1 - radiographic depth before surgery, PPD2 - periodontal pocket depth after surgery, CAL2 - clinical attachment loss after surgery, GR2 - gingival recession after surgery, R2 - radiographic depth after surgery, BF – bone filling.

Clinical attachment gain was found to be significantly and positively correlated with preoperative PPD and CAL. Similarly, periodontal pocket depth (PPD) reduction showed a strong correlation with baseline PPD and CAL values. These findings are supported by the statistically significant changes in clinical parameters—from PPD1, CAL1, and R1 to PPD2, CAL2, and R2 ($p = 0.001$). The differences are illustrated in Figure 1.

**Figure 1. Statistically significant clinical parameter's changes.**

Patients with periodontitis presenting with intrabony defects characterized by a probing depth of ≥ 6 mm and a radiographic intrabony component of ≥ 3 mm were included in the study. Defect depth

was assessed using intraoral radiographs taken with the parallel technique. In addition, intrasurgical measurements were performed to evaluate specific defect characteristics, including the number of bony walls and the size of the infraosseous component.

Bone fill was assessed radiographically at 9 months postoperatively. A portion of the results related to the number of defect walls is illustrated in Figure 2.

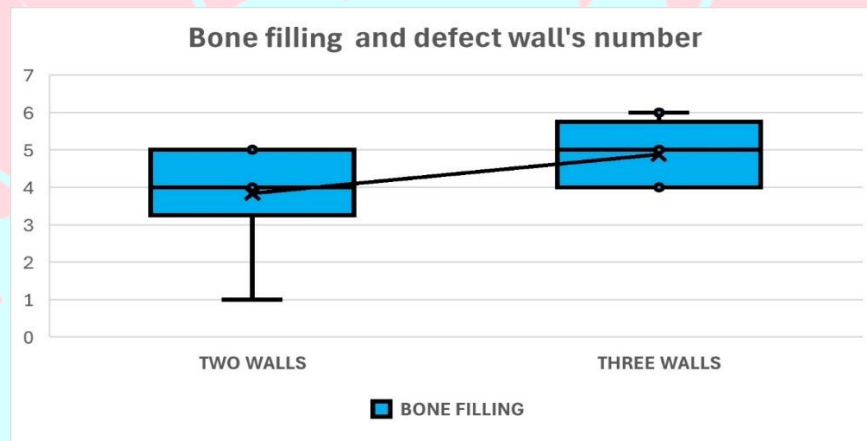


Figure 2. Relationship between bone filling and defect wall's number.

The bone defects were classified based on the angle measurements as narrow and medium-wide angles ($<36^\circ$), and wide angles ($\geq 36^\circ$). The average value of bone filling in the group with narrow and medium-wide angles is 4.88 (SD = 0.84), and in the group with wide angles – 3.83 (SD = 1.47). Although the difference between the two groups is not statistically significant (likely due to the small sample size), the results show visibly higher values in the narrow and medium-wide angles group, as illustrated in Figure 3.

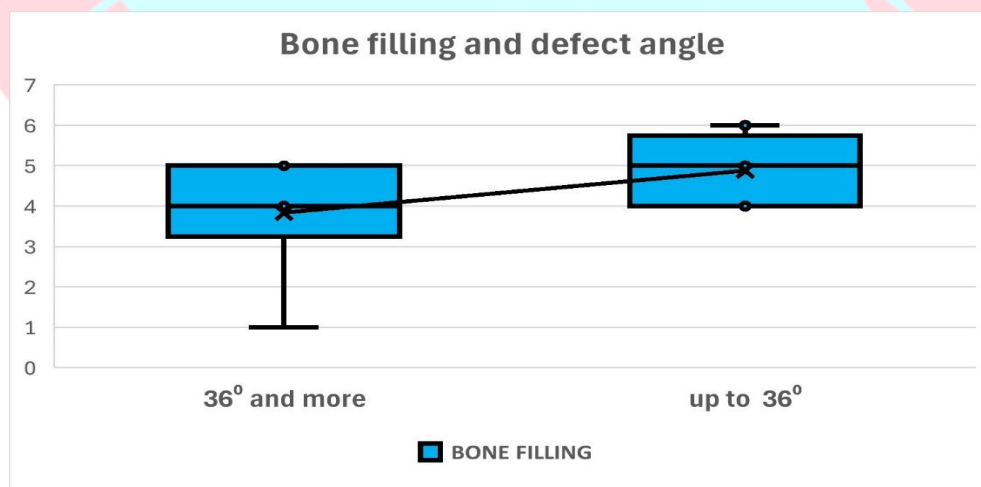


Figure 3. Relationship between bone filling and defect angle.

Discussion

Authors investigated the osteogenic cells differentiation potential of the cross-linked hyaluronic acid in an air-lift experiment model. They found HA give some benefits on the expression of osteogenic markers in osteoblast-like cells because of its prolonged degradation. (13) Thus, in accordance with the long regeneration process – up to several months. (13,14)

Shirakata et al. published histological evidences for the periodontal regeneration including new bone formation using cross-linked hyaluronic acid-gel into surgically created intrabony defects in dogs. This justifies the search for alternative options to stimulate the osteoinductive and osteoconductive properties of bone substitutes and host tissues. (15)

In addition, the study of Božić et al. comprised 23 periodontitis patients with angular defects treated with HA and xenograft. It was shown that this approach provided significant changes in clinically measured periodontal parameters – CAL and PPD ($p < 0.001$). (16)

In our investigation we obtained statistically significant data comparing clinical outcomes at baseline and 6 months after treatment ($p < 0.001$). Thus, an important positive effect of the hyaluronic acid may be suggested that favors the HA application together with bone substitutes in combinatory periodontal surgery protocol. This effect accentuates both on clinical parameters, such as PPD, CAL, GR, and radiographic variables – R, BF.

Our results showed a notable reduction of pocket's depth in the studied group of periodontitis patients from 7.29 mm to 3.07 mm ($p < 0.001$); a notable attachment gain – from 7.50 mm to 3.14 mm ($p < 0.001$). This way a significantly great pocket depth reduction was obtained (4.22 mm/mean), and near 93% pocket closure was achieved which corresponds to depth ≤ 4 mm. Moreover, we reached an important clinical attachment gain of 4.36 mm/mean.

The current study's results are in accordance with that of Bhowmik et al. who reported 5.06 mm PPD reduction when hyaluronic acid was applied in the treatment of intrabony defects; and of other researchers such as: Sehdev et al. – 4.52 mm; El-Wakeel et al. – 3.8 mm; Selvaprakash et al. – 3.27 mm; Mamajwala et al. – 5.4 mm; Engstrom et al. – 4 mm; Bojic et al. – 4.54 mm; Piloni et al. – 3.31 mm. (17- 21)

In relation to the clinical attachment gain authors presented outcomes similar to these obtained in our investigation, e.g. Bhowmik et al. – 4 mm; de Santana et al. - 4.8 mm; Selvaprakash et al. – 3.2 mm; Sehdev et al. – 4.48 mm; El-Wakeel et al. – 3.6 mm; Mamajwala et al. – 5.1 mm; El Sayed et al. – 2.87 mm; Ballini et al. - 2.8 mm/mean. (17,18,20- 22)

We were also interested on the research of Aslan et al. who noticed significant bone healing when a combination of HA and bovine bone graft was applied in rabbits. Based on the results of histopathologic specimens authors concluded that the group with HA and bone graft shows high scores compared to the control group (without HA). (23)

In our study we achieved a significant reduction in bone defect depth from 5 mm to 0.57 mm at 9 months which corresponds to 88.6 % bone fill or 4.43 mm/mean radiographic bone gain. These findings are comparable with previous reports of Bassiouny et al. – newly formed bone was $76,26 \pm 6,49\%$ but in dogs; Vela et al. – $2,67 \pm 1,20$ mm/mean bone fill baseline to 6 months; Sehdev et al. – bone fill of $3,92 \pm 0,26$ mm/mean or 94 % of the defect size in their study. (1,13,24)

The findings of our study align with existing literature data regarding the relationship between bone filling and the angle of the bone defect. Based on our results, an angle of less than 36 degrees

appears to be conducive to achieving predictable outcomes in periodontal surgery aimed at filling angular bone defects. (25)

In connection with the mentioned, our outcomes may confirm the literature data regarding the benefit of hyaluronic acid application prior to periodontal regenerative procedures. Data encourage the use of HA in combination with different biomaterials to ensure graft and flap stability, as well as the maintenance of the defect environment, which leads to bone fill and successful new bone formation. (5-7,13,16,23,26) Despite these results, strong conclusions should not be drawn due to the small scheduled group, the diversity of bone substitutes, barrier membranes, site-specific (tooth number, tooth morphology, pocket depth, defect characteristics) and patient-related conditions (psycho-emotional stress, diet, habits, and activity), protocols, etc., that may influence the healing process. We suggest these factors should be carefully analyzed.

Conclusion

The results of the current study indicate that hyaluronic acid is a promising material with good biological characteristics, making it a viable alternative to more expensive or invasive products. Further investigations are needed to provide more definitive conclusions based on clinical, radiographic, and histological findings.

Ethical statements: Informed consent was obtained from each patient and the study was performed in conformance with the position of the Committee on Research Ethics at the Medical University – Sofia and the Declaration of Helsinki ethical guidelines.

Conflict of interest statement: The authors declare that they have no conflict of interest in relation to the present study.

ACKNOWLEDGEMENT

Funding: This work was supported by the Medical University of Sofia, Agreement No D - 304/18.12.2023.

References

1. Vela OC, Boariu M, Rusu D, Iorio-Siciliano V, Sculean A, Stratul SI. Clinical and Radiographic Evaluation of Intrabony Periodontal Defects Treated with Hyaluronic Acid or Enamel Matrix Proteins: A 6-Month Prospective Study. *Oral Health Prev Dent.* 2024 Jul 12;22:257-270. doi: 10.3290/j.ohpd.b5569745. PMID: 38994786; PMCID: PMC11619917.
2. Rodríguez-Aranda M, Iborra-Badia I, Alpiste-Illueca F, Lopez-Roldan A. Hyaluronic acid for periodontal tissue regeneration in intrabony defects. A systematic review. *Dentistry Review.* 2022;2(100057) <https://doi.org/10.1016/j.dentre.2022.100057>[Google Scholar]
3. Roman D, Șufaru IG, Pășarin L, Roman L, Teslaru S, Săveanu I, Iovan G, Solomon SM. The role of hyaluronic acid in periodontitis therapy. *Romanian Journal of Oral Rehabilitation* 2023; 15(2):343-351.

4. Fawzy El-Sayed KM, Dahaba MA, Aboul-Ela S, Darhous MS. Local application of hyaluronan gel in conjunction with periodontal surgery: a randomized controlled trial. *Clin Oral Investig.* 2012;16(4):1229–36.
5. Ostos-Aguilar, B. I., Pinheiro Furquim, C., Muniz, F. W. M. G., Faveri, M., & Meza-Mauricio, J. Clinical efficacy of hyaluronic acid in the treatment of periodontal intrabony defect: a systematic review and meta-analysis. *Clinical oral investigations* 2023;27(5):1923–1935. <https://doi.org/10.1007/s00784-022-04855-6>.
6. Eliezer M, Imber JC, Sculean A, Pandis N, Teich S. Hyaluronic acid as adjunctive to non-surgical and surgical periodontal therapy: A systematic review and meta-analysis. *Clin Oral Invest.* 2019;23:3423–3435. doi: 10.1007/s00784-019-03012-w. [DOI] [PubMed] [Google Scholar]
7. Husseini B, Friedmann A, Wak R, Ghosn N, Khoury G, Ghoul T, Abboud CK, Younes R. Clinical and radiographic assessment of cross-linked hyaluronic acid addition in demineralized bovine bone based alveolar ridge preservation: A human randomized split-mouth pilot study. *J Stomatol Oral Maxillofac Surg.* 2023 Sep;124(4):101426. doi: 10.1016/j.jormas.2023.101426.
8. Mansour A, Acharya A, Alliot C, Eid N, Badran Z, Kareem Y, Rahman B. Hyaluronic acid in dentoalveolar regeneration: biological rationale and clinical applications. *Journal of Oral Biology and Craniofacial Research* 2024;14(2):230-235. <https://doi.org/10.1016/j.jobcr.2024.02.010>
9. Arpağ OF, Damlar I, Altan A, Tatli U, Günay A. To what extent does hyaluronic acid affect healing of xenografts? A histomorphometric study in a rabbit model. *J Appl Oral Sci.* 2018 Jan 18;26:e20170004. doi: 10.1590/1678-7757-2017-0004. PMID: 29364337; PMCID: PMC5777407.
10. Pirnazar P, Wolinsky L, Nachnani S, Haake S, Pilloni A, Bernard GW. Bacteriostatic effects of hyaluronic acid. *J Periodontol* 1999;70:370–374. doi: 10.1902/jop.1999.70.4.370. [DOI] [PubMed] [Google Scholar]
11. Asparuhova MB, Chappuis V, Stähli A, Buser D, Sculean A. Role of hyaluronan in regulating self-renewal and osteogenic differentiation of mesenchymal stromal cells and pre-osteoblasts. *Clin Oral Investig.* 2020;24(11):3923-3937. doi: 10.1007/s00784-020-03259-8. Epub 2020 Mar 31. PMID: 32236725; PMCID: PMC7544712.
12. Fujioka-Kobayashi M, Müller H, Mueller A, Lussi A, Sculean A, Schmidlin PR, Miron RJ 'In vitro effects of hyaluronic acid on human periodontal ligament cells' *BMC Oral Health* 2017; 17:44. DOI 10.1186/s12903-017-0341-1
13. Shirakata Y, Imafuji T, Nakamura T, Kawakami Y, Shinohara Y, Noguchi K, Pilloni A, Sculean A. Periodontal wound healing/regeneration of two-wall intrabony defects following reconstructive surgery with cross-linked hyaluronic acid-gel with or without a collagen matrix: a preclinical study in dogs. *Quintessence Int.* 2021;0(0):308-316. doi: 10.3290/j.qi.b937003. PMID: 33533237.
14. Nobis, B.; Ostermann, T.; Weiler, J.; Dittmar, T.; Friedmann, A. Impact of Cross-Linked Hyaluronic Acid on Osteogenic Differentiation of SAOS-2 Cells in an Air-Lift Model. *Materials* 2022, 15, 6528.
15. Zhao N, Wang X, Qin L, Zhai M, Yuan J, Chen J, Li D. Effect of hyaluronic acid in bone formation and its applications in dentistry. *J Biomed Mater Res Part A* 2016; 104A: 1560–1569.
16. Božić D, Čatović I, Badovinac A, Musić L, Par M, Sculean A. Treatment of Intrabony Defects with a Combination of Hyaluronic Acid and Deproteinized Porcine Bone Mineral. *Materials (Basel).* 2021;14(22):6795. doi: 10.3390/ma14226795. PMID: 34832196; PMCID: PMC8624958.
17. Bhowmik E, Rao DPC. Clinoradiographic evaluation of hyaluronan-nano hydroxyapatite composite graft in the management of periodontal infrabony defects. *J Indian Soc Periodontol.* 2021;25:220–227. doi: 10.4103/jisp.jisp_453_20. [DOI] [PMC free article] [PubMed] [Google Scholar]

18. Aldahlawi S. Clinical and Radiological Benefits of Hyaluronic Acid in Periodontal Infrabony Defects: A Systematic Review and Meta-analysis. *Open Dent J*, 2023; 17: e187421062304120. <http://dx.doi.org/10.2174/18742106-v17-230619-2022-115>
19. Sehdev B, Bhongade ML, Ganji KK. Evaluation of effectiveness of hyaluronic acid in combination with bioresorbable membrane (poly lactic acid-poly glycolic acid) for the treatment of infrabony defects in humans: A clinical and radiographic study. *J Indian Soc Periodontol*. 2016; 20(1):50-6. doi: 10.4103/0972-124X.170809. PMID: 27041838; PMCID: PMC4795135.
20. Pilloni A, Rojas MA, Marini L, Russo P, Shirakata Y, Sculean A, Iacono R. Healing of intrabony defects following regenerative surgery by means of single-flap approach in conjunction with either hyaluronic acid or an enamel matrix derivative: a 24-month randomized controlled clinical trial. *Clin Oral Investig*. 2021;25(8):5095-5107. doi: 10.1007/s00784-021-03822-x. Epub 2021 Feb 10. PMID: 33565017; PMCID: PMC8342388.
21. Mamajiwala AS, Sethi KS, Raut CP, Karde PA, Mamajiwala BS. Clinical and radiographic evaluation of 0.8% hyaluronic acid as an adjunct to open flap debridement in the treatment of periodontal intrabony defects: Randomized controlled clinical trial. *Clin Oral Investig*. 2021;25:5257-5271. doi: 10.1007/s00784-021-03834-7. [DOI] [PubMed] [Google Scholar]
22. Ballini, A., Cantore, S., Capodiferro, S., & Grassi, F. R. Esterified hyaluronic acid and autologous bone in the surgical correction of the infra-bone defects. *International journal of medical sciences* 2009;6(2), 65-71. <https://doi.org/10.7150/ijms.6.65>
23. Aslan M, Simsek G, Dayi E. The Effect of hyaluronic acid-supplemented bone graft in bone healing: experimental study in rabbits. *Journal of Biomaterials Applications* 20(3):209-20. DOI: 10.1177/0885328206051047
24. Bassiouny G, Alsahry T, Soliman S. Periodontal wound healing with hyaluronic acid alone or in conjunction with bovine bone graft in the treatment of class II furcation defects: A histologic and histomorphometric study. *Egyptian Dental Journal* 69(3):1963-1978. DOI: 10.21608/edj.2023.208366.2537
25. Tsitoura E, Tucker R, Suvan J, Laurell L, Cortellini P, Tonetti M. Baseline radiographic defect angle of the intrabony defect as a prognostic indicator in regenerative periodontal surgery with enamel matrix derivative. *J Clin Periodontol*. 2004 Aug;31(8):643-7. [PubMed]
26. Bhati A, Fageeh H, Ibraheem W, Fageeh H, Chopra H, Panda S. Role of hyaluronic acid in periodontal therapy (Review). *Biomed Rep*. 2022 Sep 28;17(5):91. doi: 10.3892/br.2022.1574. PMID: 36278244; PMCID: PMC9535241

Corresponding author:

Pashova-Tasseva Zdravka,
Medical University of Sofia, Bulgaria, Faculty of Dental Medicine, Department of Periodontology
email: z.pashova@fdm.mu-sofia.bg; Tel.: +359878180262

Dosseva-Panova V, Mlachkova A, Pashova-Tasseva Zdr, Ivanov Iv, Maynalovska Hr, Tosheva E, Kotsilkov K, Clinical and radiographic data for the application of hyaDENT BG® gel and Bio-Oss Collagen® in periodontitis, *J. Med. Dent. Pract.*, 2025; 12(2):2094-2103.